
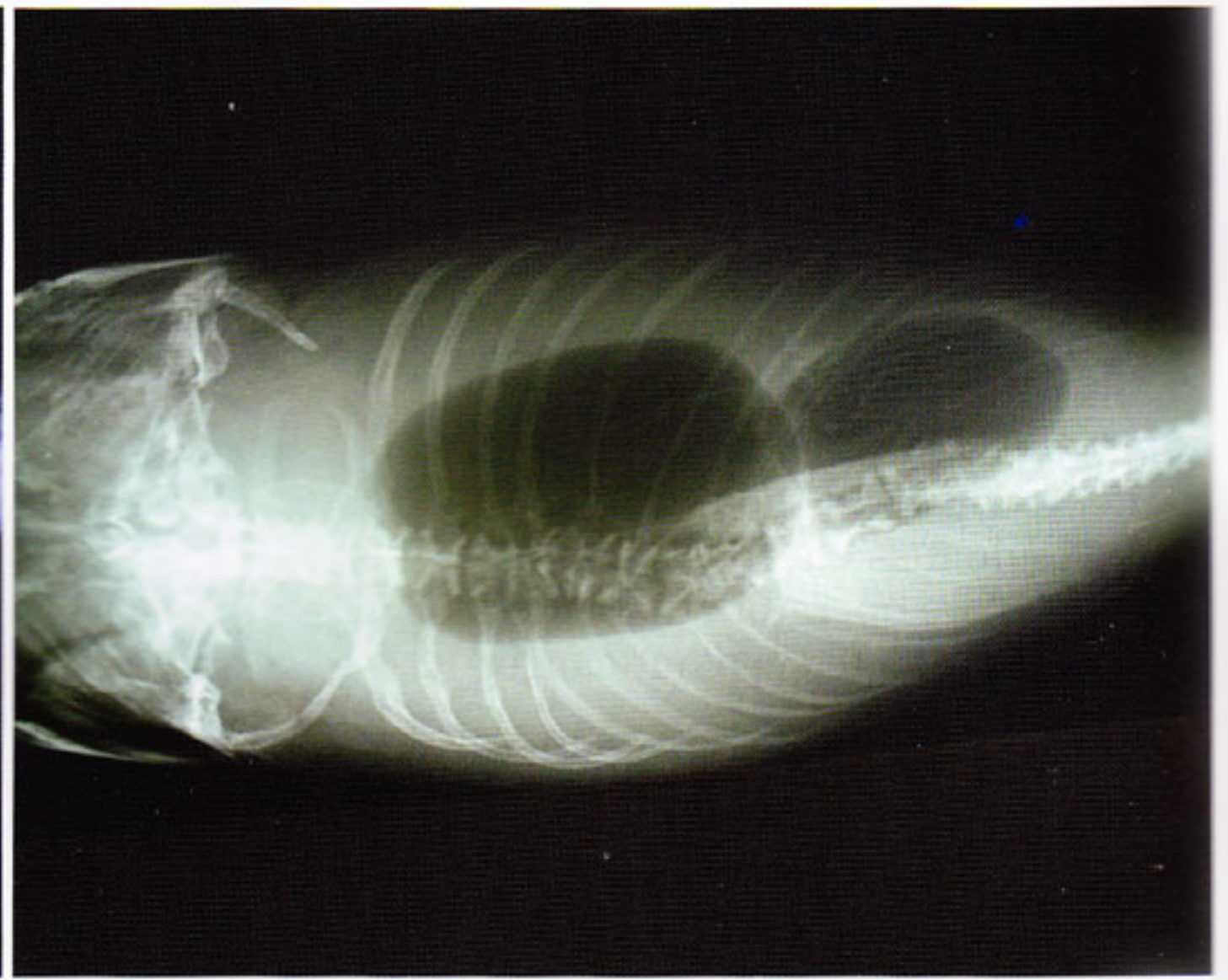


Operation in Koi: Sanke with a Swollen Abdomen



Sanke with a swollen left side of the abdomen



X-ray: a tumor pushes the posterior part of the swim bladder to the right.

by **Maarten Lammens**

photos by *Maarten Lammens*

This Sanke suffered from a swelling of the left side of its abdomen for a few months. The swelling was aggravating, and the fish had no appetite. There was no problem with the water quality, and no infections were found.

A swollen abdomen is mostly due to one of the following factors:

- Organised abscess
- Tumor or cyst (tumor in ovary or testes, liver tumor, kidney cystoma,...)
- Egg-bound
- Ascites or dropsy

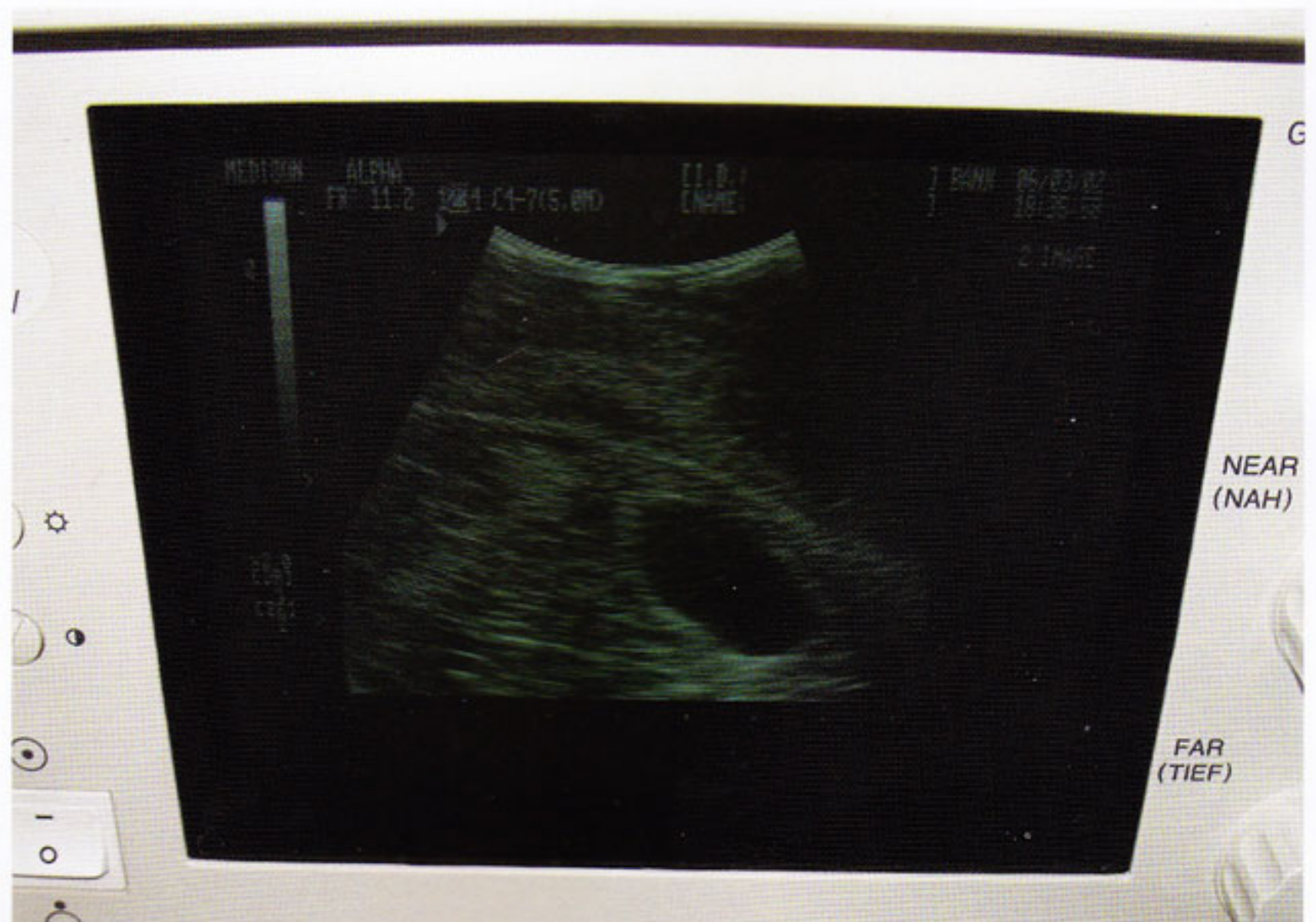An abscess, tumor or cyst, mostly causes asymmetric swellings, whereas egg-bound or dropsy mostly causes symmetric swellings.

This Sanke had a benign tumor in one hepatic lobe, which was removed as soon as possible.

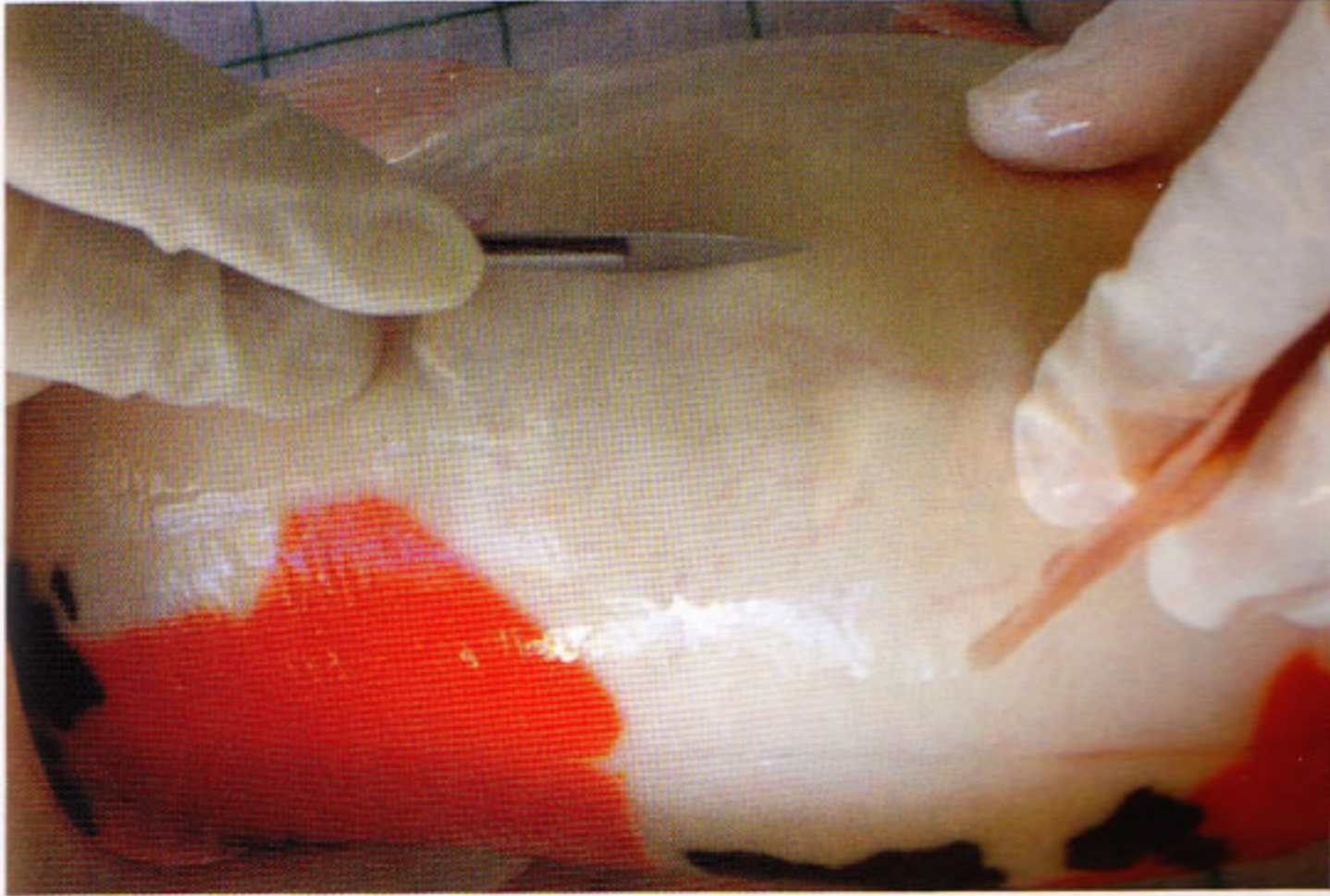
No signs of malignancy were present, so the prognosis was positive.

A few weeks after the operation, the Sanke started to eat again and after 4 years it is still doing well.

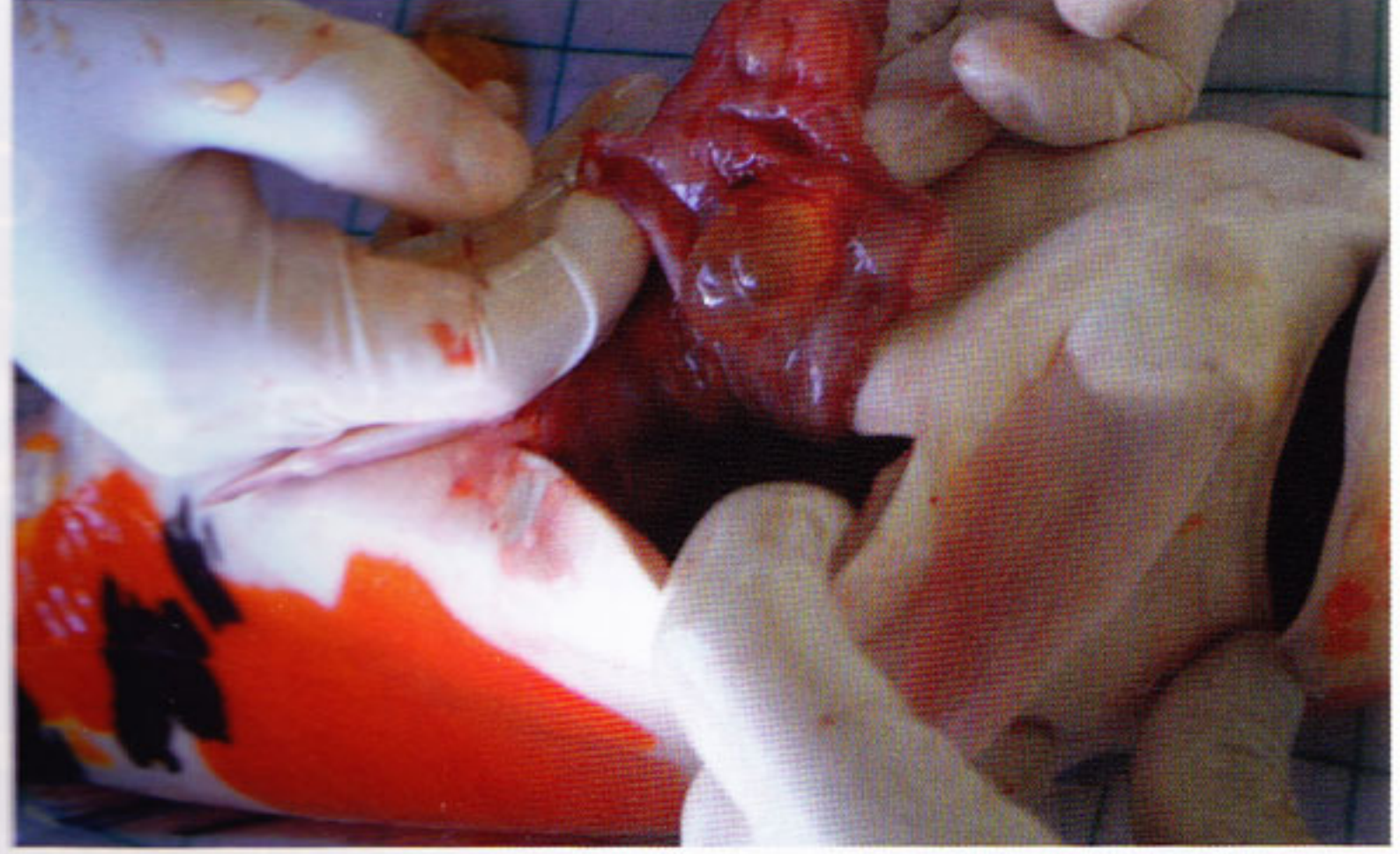Veterinarian Maarten Lammens is the author of the book "The Koi Doctor." Worldwide more than 17,000 books have been sold. For more information about the book: www.thekoidoctor.com or maartenlammens@skynet.be.



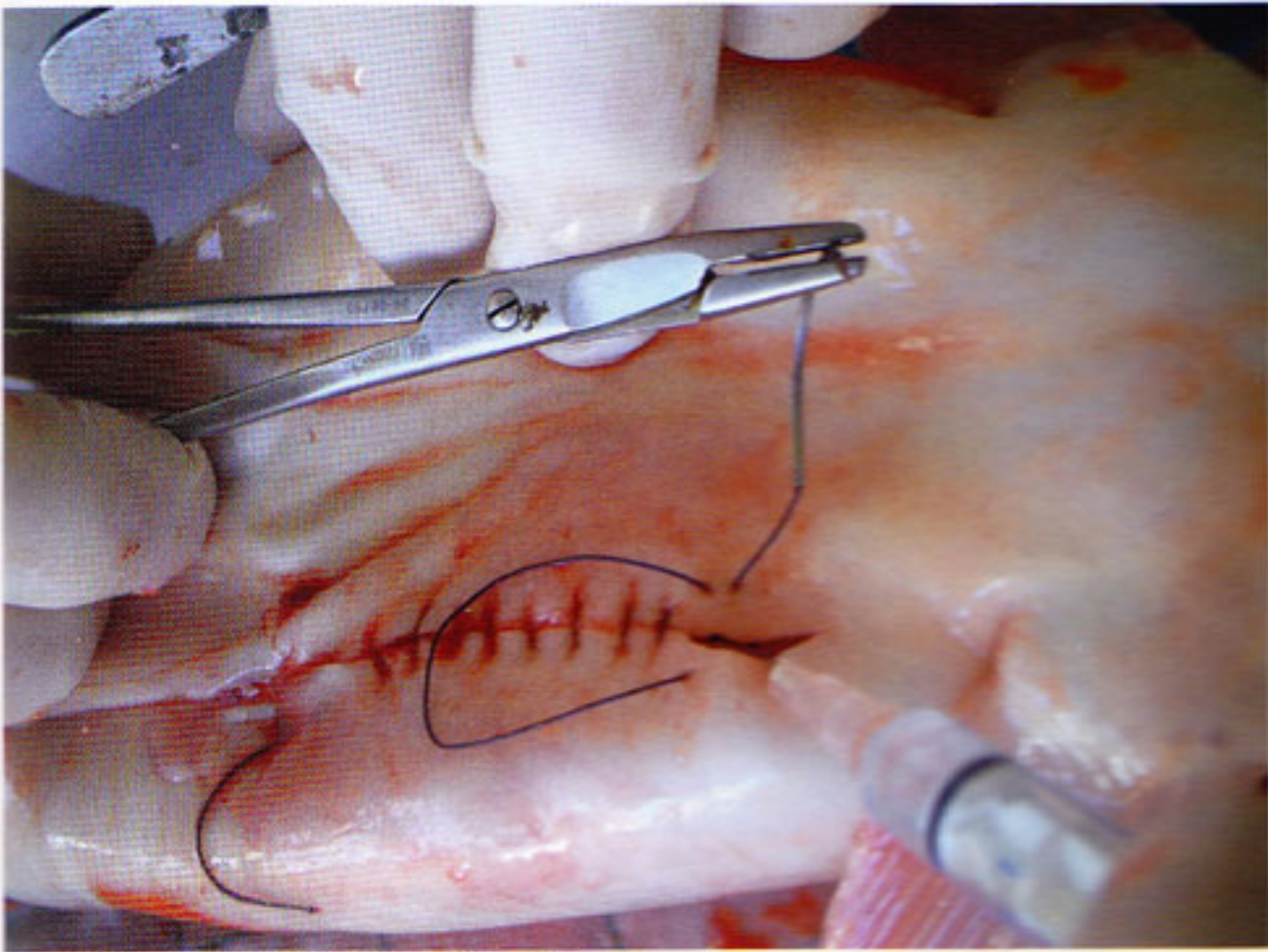
Echo: the black spots shows us the fluid of the tumor in the belly



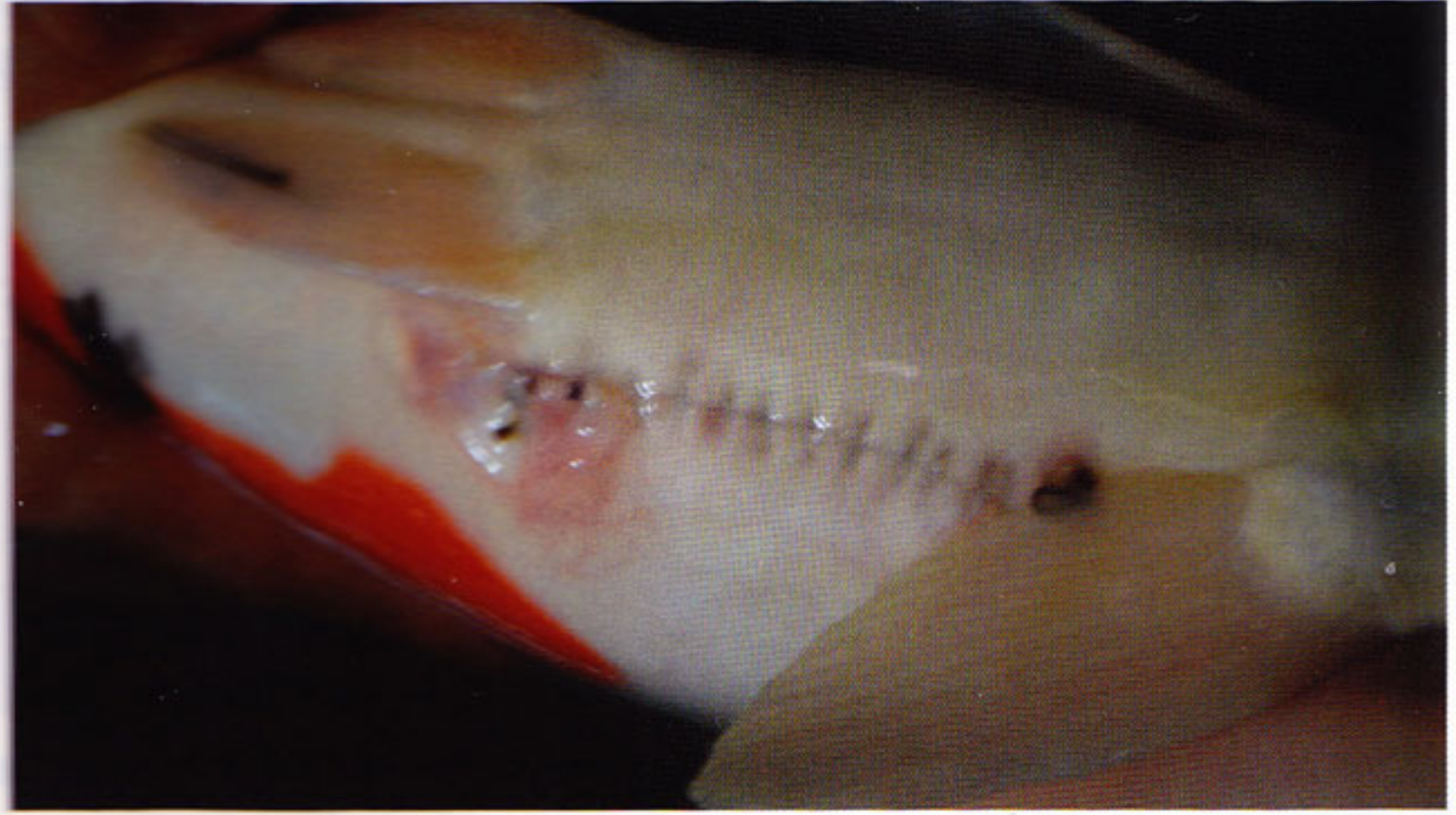Lateral incision



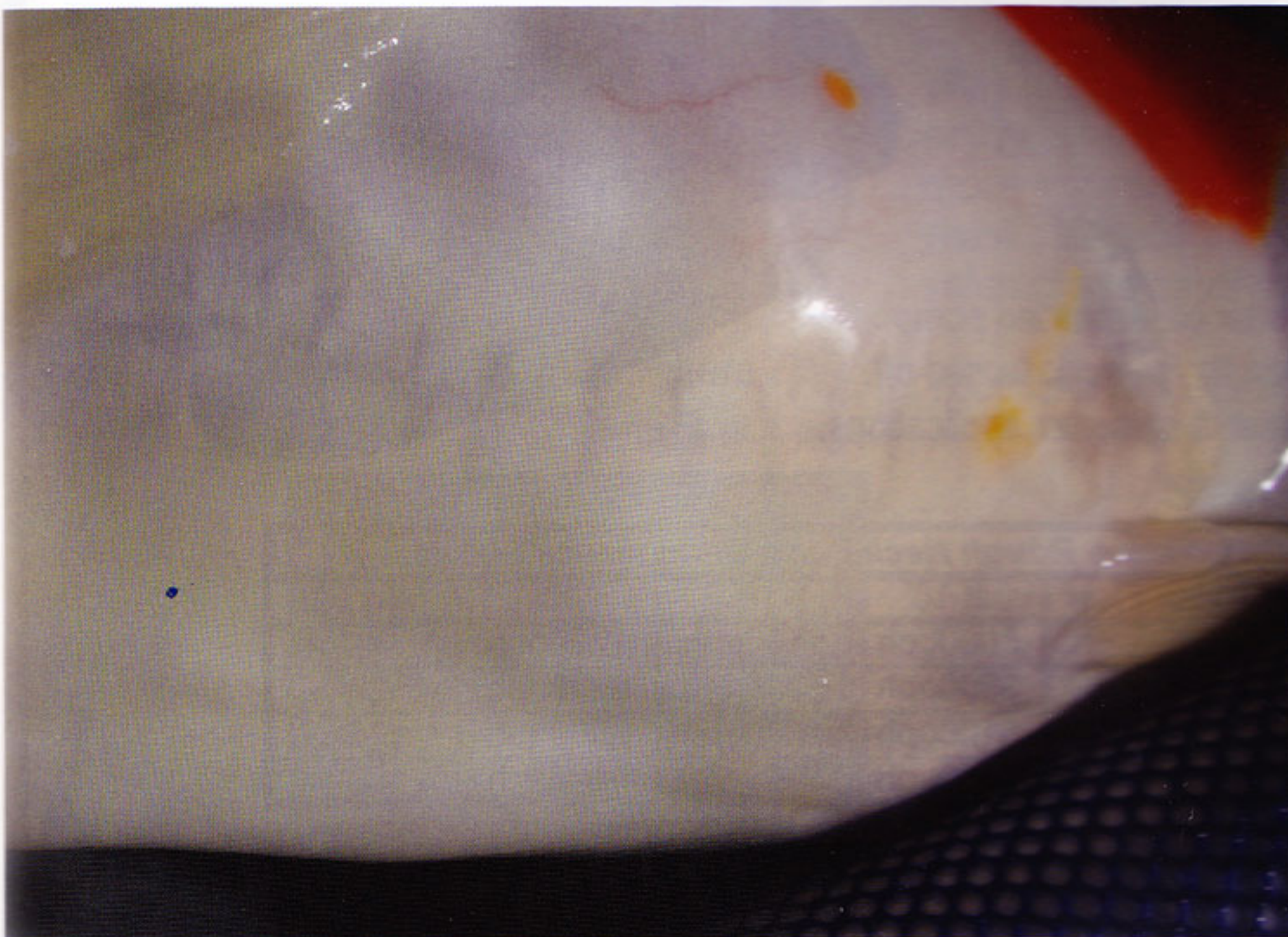
Removing the tumor



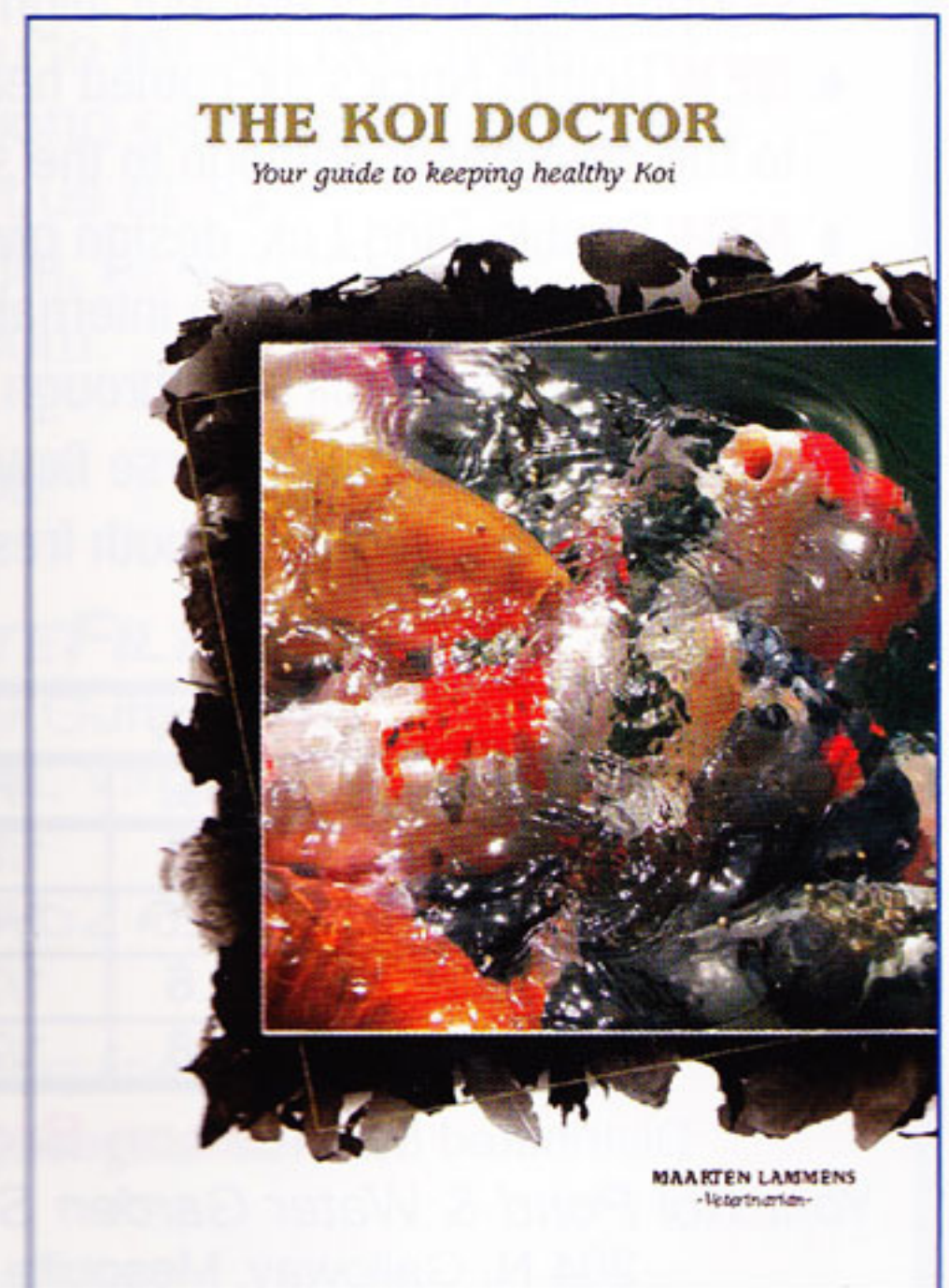
Suturing of the wound



Sutured wound healing well after 10 days



Above: Wound after 4 years



**The Koi Doctor
By Veterinarian Maarten Lammens**